

Olgu Sunumu

Left Frontal Convexity Arachnoid Cyst Extending to Interhemispheric Fissure

Nilgün ŞENOL¹, Ömer YILMAZ², Ümit Sinan ÖZDEMİR¹

¹Süleyman Demirel Üniversitesi Tıp Fakültesi, Beyin ve Sinir Cerrahisi Anabilim Dalı, Isparta

²Süleyman Demirel Üniversitesi Tıp Fakültesi, Radyoloji Anabilim Dalı, Isparta

Convexity or interhemispheric fissure arachnoid cysts are rarely seen lesions (5%). Although they are usually asymptomatic and do not require treatment, neurological symptoms like headache and seizures should be considered for surgical approaches. We reported a 47-year-old man with severe headaches. Computed tomography revealed a cystic lesion on the left cerebral convexity extending to interhemispheric fissure. Magnetic resonance imaging revealed displacement of corpus callosum with a slight midline shift caused by an arachnoid cyst. A cystoperitoneal shunt was performed. Radiologically, the cyst was partially resolved after cystoperitoneal shunting. Arachnoid cyst can cause local ischemia that triggers symptoms via compression, which can require surgical management, but an optimal treatment method can not be determined.

Key words: Arachnoid cyst, frontal, convexity, interhemispheric

J Nervous Sys Surgery 2014; 4(3):123-126

İnterhemisferik Fissüre Uzanım Gösteren Sol Frontal Konveksite Araknoid Kisti

Konveksite veya interhemisferik araknoid kistler oldukça enderdir ve %5 görülen lezyonlardır. Genellikle asemptomatik olmalarına ve tedaviye gerek olmamasına rağmen, baş ağrısı, nöbet gibi semptomların varlığı durumunda cerrahi yaklaşım düşünülebilir. Biz burada, şiddetli baş ağrısı yakınması ile başvuran 47 yaşında bir erkek hastayı sunduk. Bilgisayarlı tomografide interhemisferik fissüre uzanım gösteren sol frontal konveksite yerleşimli bir kistik lezyon tespit edildi. Manyetik rezonans görüntülemeye ise korpus kallozumun basısı ile hafif orta hat şiftine neden olan araknoid kist görüldü. Kistoperitoneal şant takıldı. Radyolojik olarak, şant sonrası kiste kısmi bir küçülme gözlemlendi. Araknoid kistler basıya yol açarak lokal iskemiye bağlı semptomların oluşmasına neden olabilirler ve bu durum cerrahi tedavi gerektirebilir, ancak tedavisinde en iyi olarak belirtilebilecek bir metod yoktur.

Anahtar kelimeler: Araknoid kist, frontal, konveksite, interhemisferik

J Nervous Sys Surgery 2014; 4(3):123-126

Intracranial arachnoid cysts are congenital developmental anomalies that occurs from splitting or duplication deformity of the arachnoid membrane and accumulation of cerebrospinal fluid in the subarachnoid space ⁽⁹⁾.

They account for 1% of all intracranial lesions ⁽¹³⁾. Middle cranial fossa (Sylvian fissure, cerebellopontine angle, suprasellar region (70%) is the frequent localization for these cysts ^(7,14). Rarely (5%), cysts locate in the convexity or interhemispheric fissure ⁽⁷⁾. Although they are frequently asymptomatic throughout life, they may sometimes cause neurological symptoms such as headaches and seizures ⁽¹⁰⁾.

Alındığı tarih: 16.07.2014

Kabul tarihi: 10.10.2014

Yazışma adresi: Yrd. Doç. Dr. Nilgün Şenol, Süleyman Demirel Üniversitesi Tıp Fakültesi, Beyin ve Sinir Cerrahisi Anabilim Dalı, Çünür / Isparta

e-mail: drnilgunsenol@yahoo.com

CASE REPORT

A 47-year-old man was admitted to our hospital with severe, progressive headache for four days. His medical history was normal. On admission, only deep tendon reflexes were hyperactive on the right side, the other neurological examination was normal. Plain radiographs of the skull were unremarkable. In the computed tomography (CT), a huge nonenhancing low-density cystic lesion with 50x75x55 mm dimensions in the left frontal region was revealed. Anterior horn of the lateral ventricle was collapsed. T1 and T2-weighted magnetic resonance images (MRI) showed compression of the corpus callosum with the cystic lesion (Figure 1, 2). There was no enhancement in contrasted MRI (Figure 3). During the operation, as the content of the cyst was dense, we inserted a cysto-peritoneal shunt with a straight connector without using the pump.

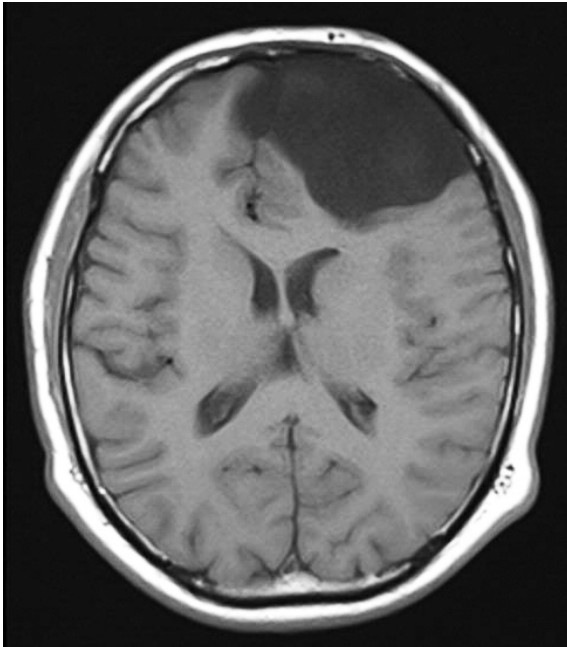


Figure 1. T1-weighted magnetic resonance image showed compression of the corpus callosum with a hypointense cystic lesion.

Postoperatively the clinical outcome was good. A small cyst was still present within the frontal convexity with reduced size and mass effect

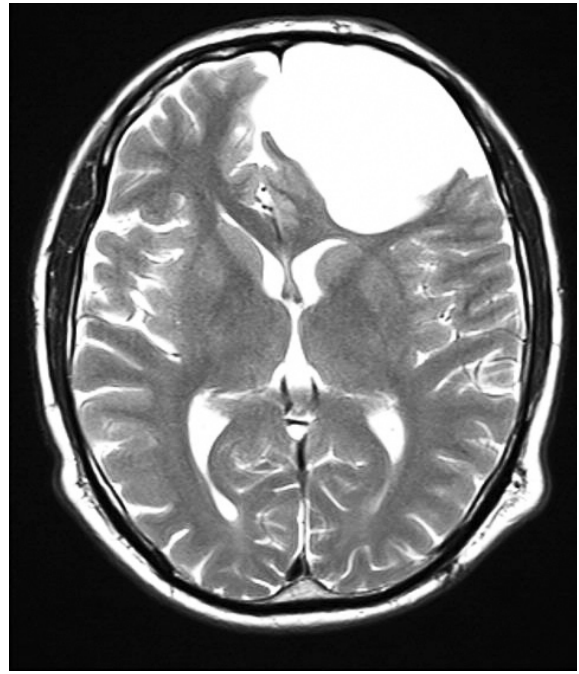


Figure 2. T2-weighted magnetic resonance image showed a hyperintense cystic lesion.

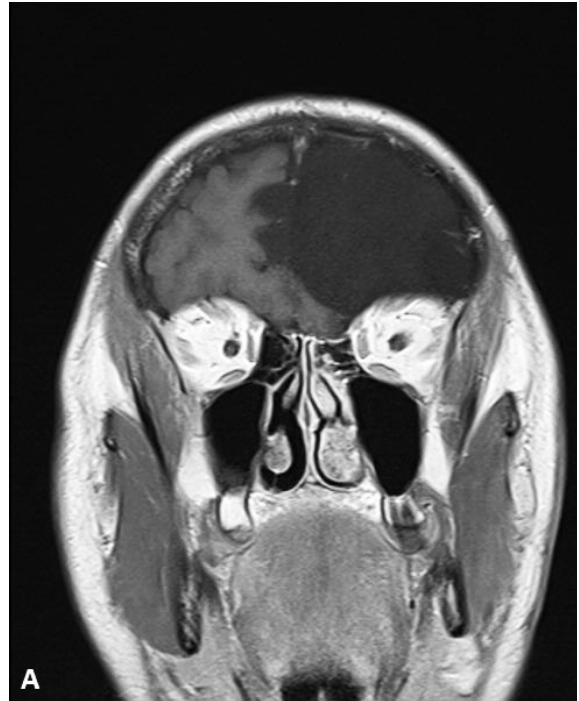


Figure 3. Axial MRI with contrast revealed no enhancement.

in the CT performed after surgery (Figure 4). In the following period the patient had no clinical complaints.

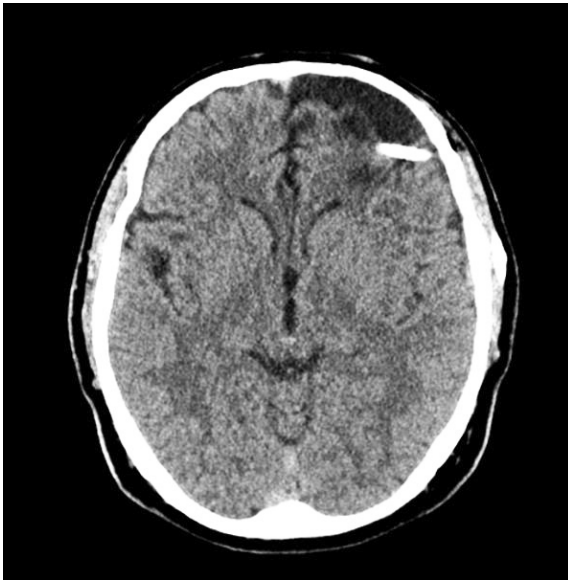

Figure 4. Postoperative CT showed a small cyst in the frontal convexity with reduced in size and mass effect.

DISCUSSION

Clinical symptoms occur mostly at an early age and rarely in the elderly, although symptomatic arachnoid cysts are uncommon⁽⁸⁾. Symptoms of arachnoid cysts include headache, seizure, motor disturbance, neuropsychological dysfunction according to localization and size. Local ischemia that triggers symptoms via compression or enlarging lesion may increase the intracranial pressure and cause symptoms⁽¹⁾. The symptoms in the elderly patients like headaches, hemiparesis, gait disorders, dementia can cause diagnostic problems as they can be seen also in chronic subdural hematoma and normal pressure hydrocephalus⁽⁷⁾.

In the literature, frontal lobe syndrome and hemiparesis are the most reported symptoms of interhemispheric arachnoid cysts in the elderly⁽⁷⁾. Yamasaki et al reported the predominant location and gender for interhemispheric arachnoid cysts as right side and females, respectively but intracranial arachnoid cyst occurs predominantly in men and left side as in our case⁽¹⁴⁾.

Although asymptomatic cysts are preferred to be followed-up, complications like subdural hematomas or intracystic hemorrhages should be kept in mind^(2,6). Also severe, and chronic gliosis of the brain as the result of increase in cystic pressure, can induce epileptic seizures that may or worsen after surgery⁽¹⁴⁾.

In the differential diagnosis neuroepithelial cysts, ependymal cysts, and colloid cysts should be considered, but the evaluation of corpus callosum for partial or complete agenesis is helpful in making the differential diagnosis as none of the interhemispheric arachnoid cysts have been associated with corpus callosum agenesis in an adult⁽⁷⁾.

Tsurushima et al reported a case with left frontal convexity arachnoid cyst that caused memory disturbance⁽¹¹⁾. Despite the presence of a huge cyst the patient in the present study had no memory disturbance, apraxia or behavior disturbance.

According to the symptoms surgical treatment can be considered to reduce the pressure caused by the cyst. Craniotomy and cyst wall excision, stereotactic cyst aspiration, cystoperitoneal shunting, endoscopic fenestration are the options for surgical treatment⁽⁷⁾. Although each procedure has advantages and disadvantages cystoperitoneal shunting can be the preferred technique because of the simplicity of the procedure.

The operative indication and appropriate surgical management are controversial issues. Some authors do not propose surgical procedures, but some authors justify the importance of surgery especially for the cysts crossed by bridging vessels to avoid intracystic hemorrhage or subdural hematoma in asymptomatic patients^(3,14). Wang et al evaluated different surgical treatments to determine the most effective technique in a

series of 68 adult patients⁽¹²⁾. In this study, although reoperation rate was significantly lower in microsurgical craniotomy group relative to cystoperitoneal shunting group, it was a more invasive technique than microsurgical craniotomy⁽¹²⁾. Endoscopic treatment is a newest technique. It can be preferred for all kinds of intracranial arachnoid cysts, but it is more effective for suprasellar, quadrigeminal and posterior region cysts. Microsurgical fenestration and shunting are more effective techniques for cortical cysts⁽⁴⁾. Excision of the cyst wall can be preferred for deeply located arachnoid cysts^(2,14).

The reason for our preference for shunting for the patient we present, was to avoid over drainage and to prevent the sudden changes in intracranial pressure as signified in the literature, in addition to its simplicity^(5,15). Although in the literature a low-pressure shunt system with a small intracystic catheter is suggested for these cysts, we used a straight connector without using the pump for the cysts with high protein content⁽⁷⁾.

In conclusion, since there is no gold standard, surgical management for each arachnoid cyst should be determined independently.

REFERENCES

1. Callaway MP, Renowden SA, Lewis TT, Bradshaw J, Malcolm G, Coakham H. Middle cranial fossa arachnoid cysts: not always a benign entity. *Br J Radiol* 1998;71:441-3. <http://dx.doi.org/10.1259/bjr.71.844.9659139>
2. Ciricillo SF, Cogen PH, Harsh GR, Edwards MSB. Intracranial arachnoid cyst in children. A comparison of the effects of fenestration and shunting. *J Neurosurg* 1991;74:230-5. <http://dx.doi.org/10.3171/jns.1991.74.2.0230>
3. Dyck P, Gruskin P. Supratentorial arachnoid cysts in adults. A discussion of two cases from a pathophysiologic and surgical perspective. *Arch Neurol* 1977;34:276-9. <http://dx.doi.org/10.1001/archneur.1977.00500170030004>
4. Gangemi M, Seneca V, Colella G, Cioffi V, Imperato A, Maiuri F. Endoscopy versus microsurgical cyst excision and shunting for treatment intracranial cysts. *J Neurosurg Pediatr* 2011;8:158-64. <http://dx.doi.org/10.3171/2011.5.PEDS1152>
5. Hamid NA, Sgouros S. The use of an adjustable valve to treat over-drainage of a cyst-peritoneal shunt in a child with a large sylvian fissure arachnoid cyst. *Childs Nerv Syst* 2005;21:991-4. <http://dx.doi.org/10.1007/s00381-004-1072-6>
6. Hoffman HJ. Gender distribution and sidedness of middle fossa arachnoid cysts: a review of cases diagnosed with computed imaging. *Neurosurgery* 1992;31: 94.
7. Kotil K, Balci N, Bilge T. Intracranial symptomatic giant arachnoid cyst of the interhemispheric fissure presenting with frontal lobe syndrome. *Turkish Neurosurgery* 2007;17(2):147-51.
8. Laribi S, Chakroun O, Segal N, Hamdi S, Plaisance P. Intracranial symptomatic giant arachnoid cyst. *Signa Vita* 2012;7(1):43-5.
9. Rengachary SS, Watanabe I. Ultrastructure and pathogenesis of intracranial arachnoid cysts. *J Neuro-pathol Exp Neurol* 1981;40:61-83. <http://dx.doi.org/10.1097/00005072-198101000-00007>
10. Sun L, Sun Z, Xuchen M. Intracranial arachnoid cyst on dental radiography: a diagnostic challenge. *Oral and Maxillofacial Radiology* 2013;115(3):53-9. <http://dx.doi.org/10.1016/j.o000.2012.07.483>
11. Tsurushima H, Harakuni T, Saito A, Tominaga D, Hyodo A, Yoshii Y. Symptomatic arachnoid cyst of the left frontal convexity presenting with memory disturbance. *Neurol Med Chir (Tokyo)* 2004;40:339-41. <http://dx.doi.org/10.2176/nmc.40.339>
12. Wang C, Liu C, Xiong Y, Han G, Yang H, Yin H, et al. Surgical treatment of intracranial arachnoid cyst in adult patients. *Neurology India* 2013;61(1):60-4. <http://dx.doi.org/10.4103/0028-3886.108013>
13. Wester K. Peculiarities of intracranial arachnoid cysts: location, sidedness, and sex distribution in 126 consecutive patients. *Neurosurgery* 1999;45(4):775-9. <http://dx.doi.org/10.1097/00006123-199910000-00008>
14. Yamasaki F, Kodama Y, Hotta T, Taniguchi E, Eguchi K, Yoshioka H, et al. Interhemispheric arachnoid cyst in the elderly: case report and review of the literature. *Surg Neurol* 2003;59:68-74. [http://dx.doi.org/10.1016/S0090-3019\(02\)00876-5](http://dx.doi.org/10.1016/S0090-3019(02)00876-5)
15. Zhang B, Zhang Y, Ma Z. Long term results of cystoperitoneal shunt placement for the treatment of arachnoid cysts in children. *J Neurosurg Pediatr* 2012;10:302-5. <http://dx.doi.org/10.3171/2012.7.PEDS11540>