

Tuberculosis of the Cervical Spine Presenting as “Compression Fracture”

Çetin Refik KAYAOĞLU, Gökşin ŞENGÜL, Aykut SEZER, Sencer DUMAN, İsmail Hakkı AYDIN

Department of Neurosurgery, University of Ataturk, Erzurum

✓ An unusual case is reported in a 45-year-old man with tuberculosis of the cervical spine presenting as “compression fracture”. Following a trauma, she had neck pain, restricted neck movements, weakness and hypoesthesia of the left arm. Plain radiograms of the cervical spine revealed marked kyphosis and compression fractures of the fifth cervical vertebra. Magnetic Resonance Imaging demonstrated destruction of C5 vertebral body. Laboratory studies confirmed the diagnosis of Pott’ disease. The patient was operated urgently via the anterior approach and underwent corpectomy and fusion. Surgical treatment was combined with medical therapy. Postoperative course was uneventful.

Key words: Tuberculosis, compression fracture, surgical treatment, cervical spine

J Nervous Sys Surgery 2008; 1(4):243-246

Kompresyon Kırığı Olarak Başvuran Servikal Vertebra Tüberkülozu

✓ Kompresyon kırığı olarak sunulan 45 yaşında erkek bir hastanın servikal vertebraındaki olağan dışı tüberkülozu rapor edildi. Travmayı takiben boyun ağrısı, boyun hareketlerinde kısıtlılık, sol kolda kuvvetsizlik ve hipoestezi vardı: Servikal omurganın düz filmleri 5. servikal vertebraanın belirgin kifoza ve kompresyon kırığını açığa çıkardı. Manyetik rezonans görüntüleme C5 vertebra gövdesindeki destrüksiyonu gösterdi. Laboratuvar çalışmaları Pott hastalığının tanısını doğruladı. Hasta acilen anterior girişimle ameliyat edildi ve korpektomi ve füzyon yapıldı. Cerrahi tedavi medikal tedavi ile kombine edildi. Postoperatif seyir problemsizdi.

Anahtar kelimeler: Servikal omurga, tüberküloz, kompresyon kırığı, cerrahi tedavi

J Nervous Sys Surgery 2008; 1(4):243-246

Spinal tuberculosis (TB) or Pott’s disease is the most common type of skeletal TB. This disease commonly affects the thoracolumbar spine and involvement of cervical spine is seen rarely. The incidence of cervical spinal tuberculosis is reported in about 6-9 % of all spinal TB ^(1,9,10,14).

The cervical TB is the most dangerous form of spinal TB and, the risks of quadriplegia and death is high. Diagnosis of the cervical TB shows some difficulties because of asymptomatic patients, or atypical and non-specific

symptoms ^(19,21). It may be evaluated as compression fracture, when radiology of the the spine shows vertebral collapse ^(5,7).

Currently surgery plays a significant role in the treatment of spinal TB, but the main therapy of this disease remains classical antituberculosis therapy using antituberculosis drugs. However, kyphotic deformity cannot be prevented only by antituberculosis therapy, and neurological recovery is slower by non-surgical treatment and total cure is possible only in a smaller percentage of cases ⁽²⁻⁴⁾.

We reported a case with cervical TB that was initially diagnosed as C5 compression fractures after trauma.

CASE REPORT

A 45 year-old man with C5 compression fracture was referred to our clinic from another hospital. Neck pain, limitation of neck movements, weakness and hypoesthesia of left arm were detected on neurological examination. He had a cervical trauma history three days earlier. Medical history showed diabetes mellitus and renal failure.

On physical examination, the patient was afebrile. Neither lymphadenopathy nor signs of pulmonary TB were detected, and cardiac examination was normal. Neck movements were limited, and local sensitivity was apparent. On neurological examination severe motor loss of the left arm was detected and the left biceps reflex was hypoactive. Hypoesthesia was found on the anterior part of the left arm. Pathological reflexes were not detected. Routine blood examination showed normal hemogram, and the erythrocyte sedimentation rate was 20 mm at the end of one hour. Skin tuberculin test was negative.

Chest X-ray was normal, and plain radiography of the cervical spine showed significant kyphosis and compression fractures of C5 vertebrae.

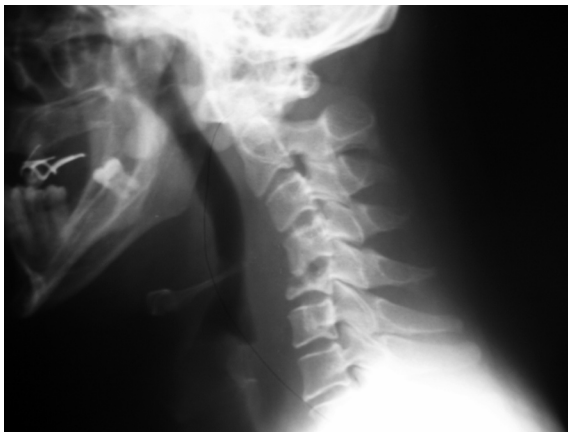

Figure 1. Lateral cervical radiography shows marked decrease in the height of the 5th vertebrae corpus in consistency with compression fracture.

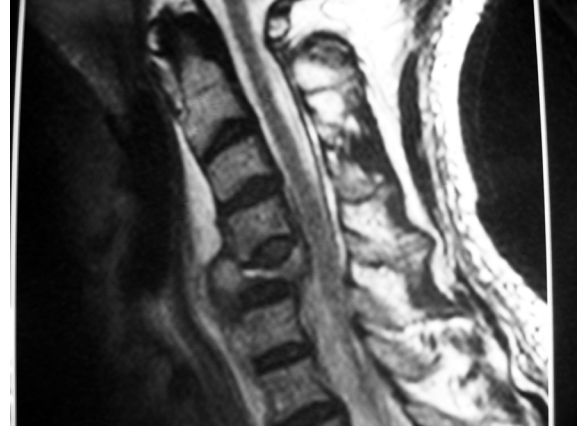


Figure 2. TSE T2-weighted sagittal MR image shows compression fracture at the 5th vertebrae corpus. Compressed vertebral body dislocated posteriorly. Anterior epidural space narrowed significantly.

There was also dislocation of bone fragments through the spinal canal (Figure 1). On magnetic resonance imaging (MRI) compression fracture at the 5th vertebrae corpus was detected. Vertebral body of compressed C5 was dislocated posteriorly, and epidural space was significantly narrowed (Figure 2).

The patient was operated emergently, and decompression and fusion with instrumentation were performed by anterior approach. The treatment was combined with antituberculosis drugs and antibiotics. Philadelphia collar was given for three months for cervical immobilisation.

Patients' symptoms were improved significantly, and he was discharged one week after surgery.

DISCUSSION

Tuberculosis has a worldwide distribution, with a greater prevalence in developing countries. The most common site of osseous involvement is the spine, which is affected in 5-15 % of cases^(12,20). Cervical involvement is unusual. However, the incidence of cervical TB is probably less than 1 % of all cases of spinal tuberculosis^(19,22).

In the spinal TB, symptoms are usually insidious and disease progression is slow, although acute

onset of spinal TB has been reported. Symptom duration at diagnosed ranges from 2 weeks to several years^(16,18). Neck pain coupled with limited neck movement is the most common symptom of cervical TB. Kyphotic deformity, torticollis, respiratory obstruction, dysphagia, trismus and XIIth nerve palsy are the other symptoms⁽¹⁷⁾. Some patients may be asymptomatic, while others may present with atypical and non-specific symptoms^(19,21). Our patient had no previous symptoms of illness. After his accident, pain with restricted movement, weakness and hypoesthesia of the left arm occurred.

A positive tuberculin test has been shown in 61-100 % patients of spinal TB. Although positive tuberculin test supports diagnosis of the TB, negative tuberculin test cannot eliminate tuberculosis infection^(2,13). Tuberculin test was negative in our patient, as in the case of Dass et al⁽⁵⁾.

Spinal TB is diagnosed by plain radiography, computed tomographic (CT) scans, MRI, radio-nuclide bone scanning, and percutaneous needle biopsy⁽¹⁸⁾. Plain radiographs demonstrate bone destruction, vertebral osteolysis and disc space narrowing^(4,13). CT scans are of considerable assistance in evaluating spinal TB since they demonstrate abnormalities earlier than plain radiographs and provide detailed images of bone⁽¹¹⁾. MRI has proved to be the best imaging procedure for spinal TB. In addition, MRI allows rapid determination of the mechanism of neurologic compression⁽⁶⁾.

The treatment of cervical TB changes from ambulatory chemotherapy to radical operative treatment. The objective of treatments in spinal TB are bacteriological control and stabilisation of the spine with minimal deformity. Surgical intervention may be required, especially in lesions that feature extensive bony destruction and large abscesses with the risk of spinal cord compression, as in our patient^(15,23).

Anterior spinal surgery is advocated by many authors, and it has certainly become a definitive part of the treatment of spinal TB. Anterior spinal surgery has been reported to produce a good outcome with reduction of kyphosis^(10,12,15,23). It is performed by decompression and fusion with or without instrumentation for cervical TB. Instrumentation following graft placement might be an alternative strategy for management of patients with cervical TB. This may reduce the incidence of graft displacement and allow for early mobilisation of the patient. The safety of instrumentation in the presence of active tuberculosis infection has been reported^(15,17,23). Instrumentation has also been reported to provide better reduction of deformity^(8,10).

In conclusion, early diagnosis and treatment of spinal tuberculosis are essential in order to prevent neurological deficits. In developing countries most cases reach hospitals at later stages, delaying diagnosis. Particularly in asymptomatic patients when roentgenograms of the spine shows vertebral collapse, spinal TB may be mistaken for compression fractures delaying the true diagnosis Pott's disease.

KAYNAKLAR

1. **Abou-Raya S and Abou-Raya A.** Spinal tuberculosis: overlooked? *J Internal Medicine* 2006; 260:160-3.
2. **Al-Sebai MW, Al-Khawashki H, Al-Arabi K, Khan F.** Operative treatment of progressive deformity in spinal tuberculosis. *Int Orthop* 2001; 25(5):322-5.
3. **Azzam NI, Tammawy M.** Tuberculous spondylitis in adults: diagnosis and treatment. *Br J Neurosurg* 1988; 2(1):85-91.
4. **Cotten A, Flipo RM, Drouot MH, Maury F, Chastanez P, Duquesnoy B, et al.** Spinal tuberculosis. Study of clinical and radiological aspects from a series of 82 cases. *J Radiol* 1996; 77:419-26.
5. **Dass B, Puet TA, Watanakunakorn C.** Tuberculosis of the spine (Pott's disease) presenting as "compression fractures". *Spinal Cord* 2002; 40(11):604-8.
6. **Desai SS.** Early diagnosis of spinal tuberculosis by MRI. *J Bone Joint Surg (Br)* 1994; 76(6):863-9.
7. **Dogulu F, Baykaner MK, Onk A, Celik B, Ceviker N.** Cervical tuberculosis in early childhood. *Childs Nerv Syst* 2003; 19(3):192-4.
8. **Faraj AA.** Anterior instrumentation for the treatment of spinal tuberculosis. *J Bone Joint Surg Am* 2001; 83:463-4.

9. **Govender S.** The outcome of allografts and anterior instrumentation in spinal tuberculosis. *Clin Orthop* 2002; 398:60-6.
10. **Hassan MG.** Anterior plating for lower cervical spine tuberculosis. *Int Orthop* 2003; 27(2):73-7.
11. **Jain R, Sawhney S, Berry M.** Computed tomography of vertebral tuberculosis. Patterns of bone destruction. *Clin Radiol* 1993; 47:196-9.
12. **Lifeso RM, Weaver P, Hardu EH.** Tuberculosis spondylitis in adults. *J Bone Joint Surg (Am)* 1985; 67(9):1405-13.
13. **Lindahl S, Nymann RS, Brismar J, Hugosson C, Lundstedt C.** Imaging of tuberculosis IV. Spinal manifestations in 63 patients. *Acta Radiol* 1996; 37(4):506-11.
14. **Locham KK, Garg R, Singh M.** Tuberculosis of Lower Cervical Spine. *Indian Pediatrics* 2001; 38(5):546-9.
15. **Loembe PM.** Tuberculosis of the Lower Cervical Spine (C3-C7) in Adults: Diagnostic and surgical Aspects. *Acta Neurochirurgica* 1994; 131(1-2):125-9.
16. **Mauri F, Laconetta G, Gallicchi B, Monto A, et al.** Spondylodiscitis. Clinical and magnetic resonance diagnosis *Spine* 1996; 22:1741-6.
17. **Oga M, Ariozon T, Tabasita M, Sugioka Y.** Evaluation of the risk instrumentation as a foreign body in spinal tuberculosis. Clinical and biological study. *Spine* 1993; 18:1890-4.
18. **Pertuiset E, Beaudreuil J, Liote F, Horusitzky A, et al.** Spinal tuberculosis in adult. A study of 103 cases in a developed country 1980-1984. *Medicine* 1999; 78(5):309-20.
19. **Raut AA, Narlawar RS, Nagar A, Ahmed N, Hira P.** An unusual case of CV junction tuberculosis presenting with quadriplegia: *Spine* 2003; 15:309-12.
20. **Slatter RR, Beale RW, Bullitt E.** Pott's disease of the cervical spine. *South Med J* 1991; 84:521-3.
21. **Turgut M.** Multifocal extensive spinal tuberculosis (Pott's disease) involving cervical, thoracic and lumbar vertebrae. *Br J Neurosurgery* 2001; 15(2):142-6.
22. **Wurtz R, Quader Z, Simon D, Langer B.** Cervical tuberculous vertebral osteomyelitis: case report and discussion of the literature. *Clin Infect Dis* 1993; 16:806-8.
23. **Yılmaz C, Selek HY, Gurkan I, Erdemli B, Korkusuz Z.** Anterior Instrumentation for the treatment of spinal tuberculosis: *J Bone Joint Surg Am* 1999; 81(9):1261-7.