

Relapsed Multiple Myeloma Presenting with an Intracranial Plasmacytoma Mimicking a Convexity Meningioma

Haldun Şükrü ERKAL¹, Emin KAYA², Çağatay ÖNAL³, İclal GÜRSES⁴

¹ Department of Radiation Oncology, İnönü University Faculty of Medicine, Malatya

² Department of Hematology, İnönü University Faculty of Medicine, Malatya

³ Department of Neurosurgery, İnönü University Faculty of Medicine, Malatya

✓ A 67 year-old woman presented with pronounced headache and vomiting that had progressed over one week. One year ago, she had been diagnosed as having multiple myeloma and had been treated with first-line chemotherapy. Her physical examination revealed marked left-sided hemiparesis. On magnetic resonance imaging of the brain, a right-sided mass lesion that appeared to originate from the meninges was associated with intense oedema that resulted in shift of midline structures. The presumptive diagnosis of a convexity meningioma was made. The patient underwent an emergency craniotomy with resection of the mass lesion and was diagnosed as having an intracranial plasmacytoma. The decision was made to proceed with radiation therapy. In the interim, the patient was diagnosed as having relapsed multiple myeloma and was treated with second-line chemotherapy accordingly. She was alive at the follow-up visit one year following surgery.

Key words: Multiple myeloma, intracranial plasmacytoma, convexity meningioma, surgery, radiation therapy, chemotherapy

J Nervous Sys Surgery 2008; 1(3):173-175

Konveksite Meningiomunu Taklit Eden Kafaıçı Plazmositom ile Bulgu Veren Nüks Multipl Miyelom

✓ Altmış yedi yaşında bayan hasta bir haftadır artan belirgin başağrısı ve kusma öyküsü ile acilen başvurdu. Bir yıl önce multipl miyelom tanısı mevcut olup ilk basamak kemoterapi uygulanmıştı. Fizik muayenede belirgin sol hemiparezi belirlendi. Beyin manyetik rezonans görüntülemesinde meninkslerden köken alan ve belirgin çevresel ödem oluşturarak orta hat yapılarını sola iten sağ hemisferde kitle lezyonu saptandı. İhtimali konveksite meningiomu ön tanısı ile hastaya acil kraniyotomi ve kitle eksizyonu uygulandı. Tanı kafaıçı plazmositom olarak belirlendi. İleri tedavi radyoterapi ile sürdürüldü. Mevcut bulgularla olgu nüks multipl miyelom tanısı olarak ikinci basamak kemoterapiye geçildi. Cerrahi girişimden bir yıl sonraki takip muayenesinde hasta salımdı.

Anahtar kelimeler:

J Nervous Sys Surgery 2008; 1(3):173-175

Regarding patients with multiple myeloma, those presenting with an intracranial plasmacytoma are scarce⁽²⁾. This report introduces a patient with relapsed multiple myeloma presenting with an intracranial plasmacytoma mimicking a convexity meningioma.

CASE DESCRIPTION

A 67 year-old woman presented with pronounced headache and vomiting that had progressed over one week. One year ago, she had been diagnosed as having multiple myeloma and had been treated with first-line chemotherapy, follo-

wing which she had declined the follow-up visits. Her physical examination revealed marked left-sided hemiparesis. On magnetic resonance imaging of the brain, a right-sided mass lesion that appeared to originate from the meninges was associated with intense oedema that resulted in left-sided shift of the midline structures. Following intravenous administration of the contrast medium, the mass lesion demonstrated notable contrast enhancement. The presumptive diagnosis of a convexity meningioma was made (Figure 1). The patient underwent an emergency craniotomy with resection of the mass lesion. Due to the fact that the mass lesion appeared to invade the brain parenchyma on exposure during surgery, limited resection of the brain parenchyma was undertaken as well. Macroscopical examination revealed a white-grey mass lesion that was rubbery in consistency and that appeared to invade the brain parenchyma. On microscopical examination, the mass lesion that appeared to originate from the meninges was compo-

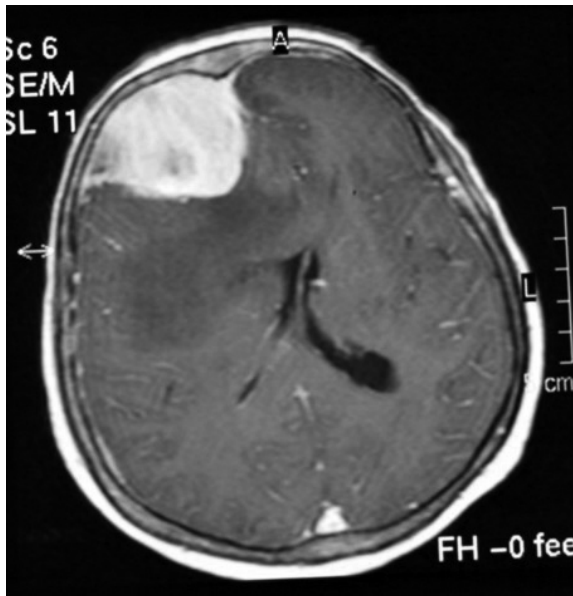


Figure 1. On magnetic resonance imaging of the brain, a right-sided mass lesion that appeared to originate from the meninges was associated with intense oedema that resulted in left-sided shift of the midline structures. Following intravenous administration of the contrast medium, the mass lesion demonstrated notable contrast enhancement. The presumptive diagnosis of a convexity meningioma was made (T2-weighted trans-axial image following intravenous administration of the contrast medium).



Figure 2. On microscopical examination, the mass lesion that appeared to originate from the meninges was composed of atypical plasma cells that were characterized by eccentric nuclei and abundant cytoplasm. The patient was diagnosed as having an intracranial plasmacytoma (Hematoxylin and eosin staining at 100 times magnification).

sed of atypical plasma cells that were characterized by eccentric nuclei and abundant cytoplasm. Immunohistochemical analysis proved positive staining for kappa light chain and epithelial membrane antigen. Therefore, the patient was diagnosed as having an intracranial plasmacytoma (Figure 2). She experienced prompt improvement and her physical examination was unremarkable apart from obscure left-sided hemiparesis at one week following surgery. Based on the fact that the mass lesion appeared to invade the brain parenchyma, the decision was made to proceed with radiation therapy. In the interim, based on the bone marrow aspiration as well as the complete blood count, the blood chemistry, the serum protein electrophoresis, the urine protein electrophoresis and the skeletal survey, she was diagnosed as having relapsed multiple myeloma and was treated with second-line chemotherapy accordingly. She was alive at the follow-up visit one year following surgery.

DISCUSSION

A plasmacytoma refers to the accumulation of atypical plasma cells at a site other than the bone marrow. The diagnosis of a plasmacytoma is based on the observation of groups of atypical

plasma cells on microscopical examination whereas immunohistochemical analysis enables the differentiation of the monoclonal groups of plasma cells from the polyclonal groups of plasma cells as well as the characterization of the monoclonal groups of plasma cells. Patients with multiple myeloma might occasionally present with an intracranial plasmacytoma that originates from the meninges, the brain parenchyma or the skull ⁽²⁾. An intracranial plasmacytoma characteristically follows an aggressive course and the treatment remains controversial. Treatment options include surgery, radiation therapy and chemotherapy. In the absence of the randomized data comparing the treatment options, the decisions are based on the non-randomized data and the institutional policies. Surgery alone appears to be appropriate for an undersized intracranial plasmacytoma, for which complete resection is most likely to be performed ⁽¹⁾. For a sizable intracranial plasmacytoma bearing features of compression and invasion,

for which complete resection is not likely to be performed, radiation therapy might either follow or replace surgery ⁽³⁾. Chemotherapy alone appears to be inappropriate, whereas chemotherapy following either surgery or radiation therapy remains to be proven. Nevertheless, an occasional patient presenting with a sizable intracranial plasmacytoma, bearing features of compression and invasion and causing devastating symptoms, might experience durable relief following treatment.

REFERENCES

1. **Bindal AK, Bindal RK, van Loveren H, Sawaya R.** Management of intracranial plasmacytoma. *J Neurosurg* 1995; 83:218-21.
2. **Schwartz TH, Rhiew R, Isaacson SR, Orazi A, Bruce JN.** Association between intracranial plasmacytoma and multiple myeloma: Clinicopathological outcome study. *Neurosurgery* 2001; 49:1039-44.
3. **Vujovic O, Fisher BJ, Munoz DG.** Solitary intracranial plasmacytoma: Case report and review of management. *J Neurooncol* 1998; 39:47-50.