

## Persistent Median Artery: Case Report and Review of the Literature

Yasin ARİFOĞLU <sup>1</sup>, Özdemir SEVİNÇ <sup>2</sup>, Çağatay BARUT <sup>3</sup>, Merih İŞ <sup>4</sup>,  
Murat DIRAMALI <sup>1</sup>

<sup>1</sup> Abant, İzzet Baysal Tıp Fakültesi, Anatomi Anabilim Dalı, Bolu

<sup>2</sup> Düzce Üniversitesi, Tıp Fakültesi, Anatomi Anabilim Dalı, Düzce

<sup>3</sup> Karaelmas Üniversitesi, Tıp Fakültesi, Anatomi Anabilim Dalı, Zonguldak

<sup>4</sup> Düzce Üniversitesi, Tıp Fakültesi, Nöroşirürji Anabilim Dalı, Düzce

✓ A persistent median artery may supply the hand in radial or ulnar artery injuries, or it may be used as a graft artery elsewhere in the body. It may compress the median nerve and cause symptoms of carpal tunnel syndrome as well. We encountered a persistent median artery in the right upper extremity of a 55-year-old male cadaver during routine dissection. The enlarged persistent median artery ran distally and passed under flexor retinaculum, gave branches to metacarpal bones along with the branches of the median nerve. It showed no anastomosis with the superficial palmar arch. Being a common variation, it should be taken into account as it may cause carpal tunnel syndrome and it may be a useful route of blood supply to the hand in radial or ulnar artery injuries.

**Key words:** Gross anatomy, hand, variation, persistent median artery, median nerve

*J Nervous Sys Surgery 2008; 1(3):195-198*

### Persistan Mediyan Arter: Olgu Sunumu ve Literatürün Gözden Geçirilmesi

✓ Persistan mediyan arter, radyal veya ulnar arter yaralanmalarında eli besleyebilir, vücudun başka herhangi bir yerinde greft arteri olarak kullanılabilir. Ayrıca mediyan sinire bası yaparak karpal tünel sendromu semptomlarına neden olabilir. Ellibeş yaşındaki erkek kadavranın rutin kadavra diseksiyonu sırasında sağ üst ekstremitede persistan mediyan artere rastladık. Genişlemiş persistan median arter distalde seyrederek fleksör retinakulumun altından geçip median sinir dallarına paralel olarak metakarpal kemiklere dallar vermektedir. Yüzeysel palmar arkla arasında anastomoz izlenmedi. Persistan mediyan arter yaygın bir varyasyon olarak, karpal tünel sendromuna neden olması ve radyal/ulnar arter yaralanmalarında eli besleyebilen bir alternatif oluşturması nedeniyle önemlidir.

**Anahtar kelimeler:** El, makroskopik anatomi, persistan mediyan arter, varyasyon

*J Nervous Sys Surgery 2008; 1(3):195-199*

Variation in the arterial supply to the human upper limb is fairly common and has long received the attention of anatomists and surgeons <sup>(16,24,25)</sup>. The main arteries supplying the upper limb are the brachial artery in the arm, and ulnar and radial arteries in the forearm, as described in the classical and surgical textbooks <sup>(15,21,22)</sup>.

The brachial artery terminates approximately in

the middle of the cubital fossa, just distal to the elbow joint, where it divides into the radial and ulnar arteries. The radial artery is the more direct continuation of the brachial artery and it descends along the lateral side of the forearm to the wrist, curves around the lateral side of the carpal bones, passes over the floor of the anatomical snuff box, and penetrates into the dorsum of the hand. There, it passes between the two heads of the first dorsal interosseous muscle,

turns medially, and anastomoses with the deep palmar branch of the ulnar artery completing the deep palmar arch. The ulnar artery is larger than the radial artery and passes down the medial side of the forearm. It enters the hand by passing lateral to the pisiform bone and superficial to the flexor retinaculum of the wrist. Distal to this, it gives off the deep palmar branch, and arches over the palm as the superficial palmar arch. The common interosseous artery, a short branch of the ulnar artery, arises in the distal part of the cubital fossa just below the radial tuberosity, and divides almost immediately into anterior and posterior interosseous arteries. The posterior interosseous artery descends on the posterior aspect of the interosseous membrane, while the anterior interosseous artery descends on the anterior aspect and joins the dorsal carpal arch<sup>(15,21)</sup>.

In the development of the arterial system in the upper limb, the axial artery arises initially and then develops into the brachial artery in the upper arm and the interosseous artery in the forearm to provide the main supply of blood during the early embryonic period. Subsequently, the median, ulnar, and radial arteries appear as sprouts off the arterial trunk. Of these latter arteries, the median artery, together with the interosseous artery, provides the main supply of blood to the forearm and hand initially, but this normally dwindles after the second embryonic month and it is replaced by the ulnar and radial arteries. In adults, the median artery occasionally remains as a thin artery that runs along the median nerve (*arteria comitans nervi mediani*), frequently arising from the common or anterior interosseous artery<sup>(17,19,20)</sup>. It reaches the palm with the nerve, where it may join the superficial palmar arch or end as one or two palmar digital arteries.

Three criteria identify a persistent median artery, as distinct from the *arteria comitans nervi mediani*: (a) when it is shown by dissection to supply structures in the hand; (b) when it has a mini-

mum diameter exceeding 1 mm; and (c) when its diameter at origin exceeds 2 mm.<sup>(6)</sup> Its presence should be considered in clinical practice, as it may cause symptoms of carpal tunnel syndrome<sup>(5,6,10,11,16)</sup>.

Although it is a rather common variation, persistent median artery is not well documented in surgical textbooks<sup>(22)</sup> and it may cause some symptoms in certain situations such as the carpal tunnel syndrome<sup>(2-6,11,14,18,19)</sup>. So it is important to know such a variation. Here, we report the anatomical features of a persistent median artery and briefly review the literature on this specific entity.

## CASE REPORT

We encountered a persistent median artery in the right upper extremity of a 55-year-old male cadaver during routine dissection in the Anatomy Department of our Medical School. In the present case, the brachial artery divided into the radial and ulnar arteries at the cubital fossa. A digital caliper was used to measure the arterial length and distances regarding the branching sites of the arteries (BTS Digital Caliper 300×0.01 mm). The common interosseal artery originated from the ulnar artery 5 cm distal to the above-mentioned division. The common interosseal artery divided into anterior and posterior interosseal arteries after a 0.5 cm course. The persistent median artery originated from the ulnar artery 0.5 cm distal to the origin of the common interosseal artery (Figure 1). The persistent median artery ran distally and passed under the flexor retinaculum, together with the median nerve, and gave branches to the first and second metacarpals, along with the branches of the median nerve. It did not anastomose with the superficial palmar arch. The diameter of the persistent median artery was 2mm at its origin and 1.4 mm at its termination site. The entire length of this artery was 17.4 cm.

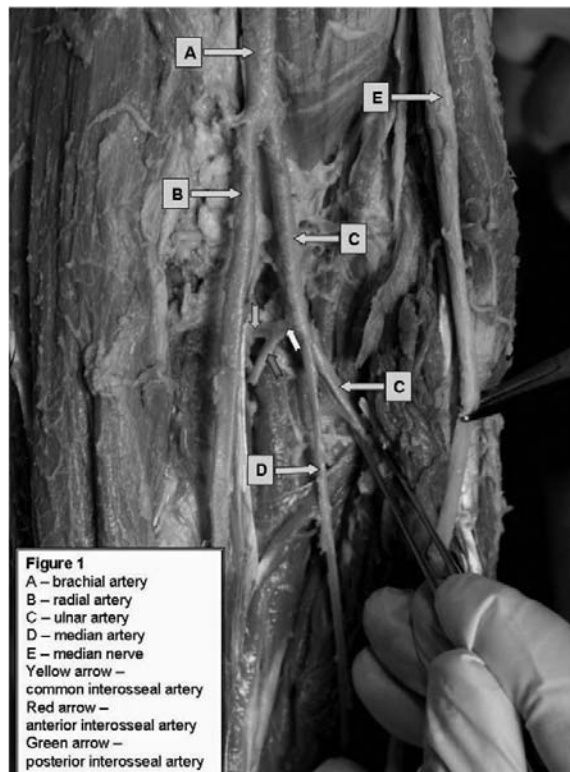


Figure 1. Branching pattern of brachial artery with the persistent median artery originating from the ulnar artery.

## DISCUSSION

Variations in the number or course of the arteries of the upper limb has surgical significance. The axillary, brachial, and interosseous arteries are derived from the primitive axial artery<sup>(16)</sup>. The median artery provides most of the supply of blood to the forearm and hand in the embryonic period. The radial and ulnar arteries are the last arteries to appear in the forearm. After the eighth week of gestation, the median artery regresses, loses its distal communications, and becomes a small vessel with the subsequent development of the radial and ulnar arteries<sup>(2,5,6,9-11,22)</sup>. In a vascular surgery book it is stressed that a persistent median artery may supplement or replace the radial or ulnar artery but no further details are given<sup>(22)</sup>. The median artery is reported to originate from the anterior interosseal artery frequently, but it can also arise from the common interosseal, ulnar, brachial, and radial arteries<sup>(1,2,19,23)</sup>. When it persists, it courses distally with

the median nerve through the carpal tunnel and may split the median nerve within the carpal tunnel<sup>(1,2)</sup>. A persistent median artery in an adult is considered to be a retained primitive arterial pattern<sup>(17)</sup>.

Persistence of a median artery is not uncommon. The reported incidence ranges from 2.2-4.4 %<sup>(1)</sup>. Lindley et al. reported an incidence of 3.4% in 526 carpal tunnel cases<sup>(12)</sup>. Lippert and Pabst reported this incidence as 8 %, <sup>(13)</sup> whereas Henneberg and George reported an incidence of 27.1 % in Southern African cadavers<sup>(5)</sup>.

Rodriguez-Niedenfuhr et al<sup>(17)</sup> described two different patterns of the persistent median artery, based on their vascular territories: the palmar and antebrachial types. In the palmar type, the artery reaches the palm of the hand, while in the antebrachial type it terminates before reaching the wrist. The median artery we encountered was a palmar type artery giving branches to the first and second digits without any contribution to the superficial palmar arch. The median artery in our case arose from the ulnar artery directly. This type of origin is not the most frequent type, but it is well documented in the literature<sup>(17)</sup>. Tsuruo et al<sup>(20)</sup> described a median artery that arose directly from the ulnar artery and gave branches to the ulnar side of the thumb and second interdigital space. Our case is similar to that of Tsuruo et al. in terms of the origin of the artery, but the terminations of the arteries differed. Our case is more similar to that of Sanudo et al<sup>(19)</sup>.

Krishnamoorthy et al<sup>(11)</sup> reported a painful right forearm with swelling extending from the elbow to the wrist, which was caused by an arteriovenous malformation; a persistent median artery with branches contributed to the swelling. Furthermore, a persistent median artery may supply the hand in radial or ulnar artery injuries, or it may be used as a graft artery elsewhere in the body, if present<sup>(6)</sup>. When it is much enlarged

and thrombosed it may compress the median nerve and cause symptoms of carpal tunnel syndrome<sup>(5,6,10,11,19)</sup>. Khashaba<sup>(8)</sup> Balakrishnan et al<sup>(2)</sup>, Barfred et al<sup>(3)</sup> Rose<sup>(18)</sup> Jackson and Campbell<sup>(7)</sup> and Lisanti et al<sup>(14)</sup> have all reported carpal tunnel syndrome caused by a thrombosed persistent median artery. Furthermore a persistent median artery may cause symptoms of carpal tunnel syndrome without being thrombosed. If the electrophysiological works do not give any extra information in patients with symptoms of carpal tunnel syndrome, this should be emphasized so<sup>(14)</sup>. In case of suspicion, color Doppler ultrasonography may be performed in order to diagnose or rule out persistent median artery<sup>(4)</sup>.

The superficial course of the persistent median artery close to the flexor retinaculum may damage the blood supply of the hand during excision. In the absence of thrombosis, median artery excision is unnecessary.

In summary, these clinical features should be considered in clinical practice and during carpal tunnel surgery.

## REFERENCES

1. **Balakrishnan C, Emanuele JA, Smith FM.** Asymptomatic persistent median artery in a trauma patient. *Injury*. 1997; 28(9-10):697-8.
2. **Balakrishnan C, Smith MF, Puri P.** Acute carpal tunnel syndrome from thrombosed persistent median artery. *J Emerg Med* 1999; 17(3):437-9.
3. **Barfred T, Hojlund AP, Bertheussen K.** Median artery in carpal tunnel syndrome. *J Hand Surg [Am]*. 1985; 10(6 Pt1):864-7.
4. **Gassner EM, Schocke M, Peer S, Schwabegger A, Jaschke W, Bodner G.** Persistent median artery in the carpal tunnel: color Doppler ultrasonographic findings. *J Ultrasound Med* 2002; 21(4):455-61.
5. **Henneberg M, George BJ.** High incidence of the median artery of the forearm in a sample of recent southern African cadavers. *J Anat* 1992; 180(Pt 1): 185-8.
6. **Henneberg M, George BJ.** A further study of the high incidence of the median artery of the forearm in Southern Africa. *J Anat* 1992; 181(Pt 1):151-4.
7. **Jackson IT, Campbell JC.** An unusual cause of carpal tunnel syndrome. A case of thrombosis of the median artery. *J Bone Joint Surg Br* 1970; 52:330-3.
8. **Khashaba A.** Carpal tunnel syndrome from thrombosed persistent median artery. *J Emerg Med* 2002; 22:55-7.
9. **Kopuz C, Gulman B, Baris S.** Persistent median artery: an anatomical study in neonatal and adult cadavers. *Kaibogaku Zasshi* 1995; 70:577-80.
10. **Koshy S, Rabi S, Indrasingh I, Vettivel S.** Two anatomical variations associated with potential vascular entrapment in the upper limb. *Eur J Anat* 2003; 7(2):97-100.
11. **Krishnamoorthy L, Murison MS, Sykes PJ.** Arteriovenous malformation of the forearm as a result of a persistent median artery. *J Hand Surg [Br]*. 1998; 23(6):820-1.
12. **Lindley SG, Kleinert JM.** Prevalence of anatomic variations encountered in elective carpal tunnel release. *J Hand Surg [Am]*. 2003; 28:849-55.
13. **Lippert H, Pabst R.** Arterial variation in man: classification and frequency. Ed. Bergmann Verlag JF, München: Springer-Verlag; 1985.
14. **Lisanti M, Rosati M, Pardi A.** Persistent median artery in carpal tunnel syndrome. *Acta Orthop Belg* 1995; 61:315-8.
15. **Moore, KL, Dalley AF.** Clinically oriented anatomy, 4th ed, Philadelphia: Lippincott Williams&Wilkins; 1999.
16. **Rodríguez-Baeza A, Nebot J, Ferreira B, Reina F, Pérez J, Sañudo JR, Roig M.** An anatomical study and ontogenetic explanation of 23 cases with variations in the main pattern of the human brachio-antebrachial arteries. *J Anat*. 1995; 187(Pt 2):473-9.
17. **Rodríguez-Niedenführ M, Sañudo JR, Vázquez T, Nearn L, Logan B, Parkin I.** Median artery revisited. *J Anat*. 1999; 195(Pt 1):57-63.
18. **Rose RE.** Acute carpal tunnel syndrome secondary to thrombosis of a persistent median artery. *West Indian Med J* 1995; 44:32-3.
19. **Sanudo JR, Chikwe J, Evans SE.** Anomalous median nerve associated with persistent median artery. *J Anat* 1994; 185(Pt 2): 447-51.
20. **Tsuruo Y, Ueyama T, Ito T, Nanjo S, Gyoubu H, Satoh K, Iida Y, Nakai S.** Persistent median artery in the hand: a report with a brief review of the literature. *Anat Sci Int*. 2006; 81(4):242-52.
21. **Williams PL, Bannister LH, Berry MM, et al.** Gray's Anatomy. Thirty-Eighth Edition, Edinburgh: Churchill Livingstone; 1995.
22. **Wind GG, Valentine RJ.** Anatomic exposures in vascular surgery, Baltimore: Williams&Wilkins; 1991.
23. **Wood SJ, Abrahams PH, Sañudo JR, Ferreira BJ.** Bilateral superficial radial artery at the wrist associated with a radial origin of a unilateral median artery. *J Anat* 1996; 189(Pt 3):691-3.
24. **Yalcin B, Kocabiyyik N, Yazar F, Kirici Y, Ozan H.** Arterial variations of the upper extremities. *Anat Sci Int*. 2006; 81(1):62-4.
25. **Yoshinaga K, Tanii I, Kodama K.** Superficial brachial artery crossing over the ulnar and median nerves from posterior to anterior: embryological significance. *Anat Sci Int* 2003; 78(3):177-80.